

Colonoscopy Procedure Report



Patient: John Smith
Patient ID: MRN-12345
Exam Date: 03/29/2010

Attending Physician: William Fambord M.D.
Referring Physician: Michael Trupnick

Introduction: A 60 year old male patient presents for an elective inpatient Colonoscopy.

Glucose Stick Test:

Pregnancy Test: N/A

Indications:

- Recent bleeding (459.0).
- Pain centered in the left lower quadrant of the abdomen (789.04).

Consent: The benefits, risks, and alternatives to the procedure were discussed and informed consent was obtained from the patient.

Preparation: EKG, pulse, pulse oximetry, and blood pressure were monitored throughout the procedure.

Medications:

- Demerol 50 mg IV during the procedure.
- Versed 2.5 mg IV during the procedure.

Rectal Exam: Normal rectal exam.

Procedure: The colonoscope was passed through the anus under direct visualization and was advanced with ease to the ileocecal valve. The scope was withdrawn and the mucosa was carefully examined.

Findings: There was evidence of moderately severe diverticulosis in the sigmoid colon. ① A single large sessile polyp was found in the ileocecal valve. It was not bleeding. ⑤ ⑥ The polyp was completely removed by hot biopsy polypectomy. The polyp was retrieved and placed in jar 1. The site was marked with 5 cc's of indigo carmine.

Unplanned Events: There were no unplanned events.

Summary:

- Moderately severe diverticulosis (562.10) found in the sigmoid colon.
- A single large sessile polyp was found in the ileocecal valve (211.3); removed by hot biopsy polypectomy. Chromoscopy procedure performed.

Recommendations:

- Avoid all non-steroidal anti-inflammatory drugs (NSAID's) including but not limited to Ibuprofen, Advil, Motrin, and Nuprin for 5 days.
- Discharge home when standard parameters are met.
- Start high fiber diet.
- Colonoscopy recommended in 1 year. Patient to schedule a future appointment today.
- Follow-up on the results of the biopsy specimens in 1 week.

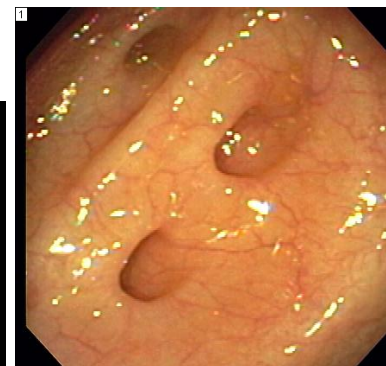
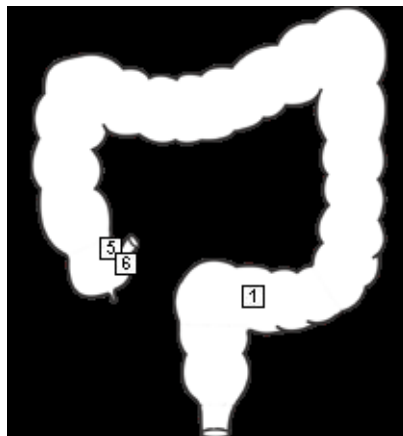
Procedure Codes:

- [45384]Colonoscopy with hot biopsy polypectomy

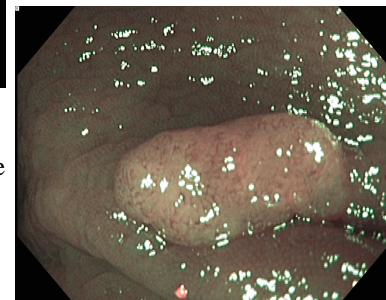
Report electronically signed by Dr. William Fambord, M.D. on 03/29/2010 at 04:14 PM

William Fambord

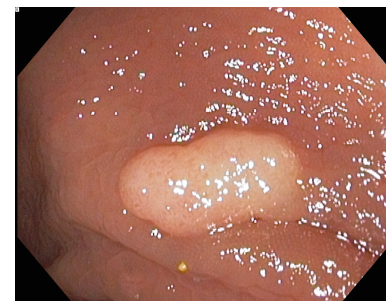William Fambord, M.D.



① diverticulosis-colon-sigmoid colon



⑤ polyp(s)-colon-ileocecal valve



⑥ polyp(s)-colon-ileocecal valve